

Electroacupuncture treatment of acute low back pain: unlikely to be a placebo response

Acupuncture is commonly used for acute low back pain (LBP), and a recent systematic review found encouraging evidence on its effectiveness compared with medication or sham acupuncture.¹ I believe your readers will be interested to hear the details of a recently treated case which is somewhat unusual, and where the patient's improvement seems likely to be more than a placebo response.

CASE SUMMARY

The patient was a 65-year-old retired Caucasian woman with good general health. In mid-March 2014 she had had a sudden onset of pain over the right lower back. She denied any history of trauma. Initially the pain was subtle, with severity scored at 2/10, diffuse, constant, aching in nature and not radiating. In the next 7 days, the pain had become moderate-to-severe. It was improved by rest to 5/10, but worsened to 7/10 with leaning forward. She did not have any history of LBP, mechanical trauma or bone fracture. She was not taking any anti-inflammatory medication or painkillers. She looked generally unwell and was obviously in pain. She was overweight. Palpation of the vertebrae and paravertebral muscles below the level of T12 did not induce the pain. The pain was exacerbated when she was asked to flex her hip and laterally rotate her right lower limb. Flexion of the hip caused more pain than other movements. It was located at about 1.5–4.0 cm right lateral to L2 to L4.

ACUPUNCTURE

A course of acupuncture was offered during her first visit in late March. Needles (stainless steel needles of 0.25 mm diameter and 40 mm length) were inserted for 25 min at the following points,

bilaterally where appropriate, without manual stimulation: BL23, BL24, BL25, BL52, BL53, BL54, GV3 and GV4. The needles at BL52 and BL54 were stimulated electrically (4 Hz) after insertion. She did not experience any *de qi* or acupuncture sensation. Immediately after removal of the needles her pain was barely improved.

At follow-up the next day, the same points were needled and again stimulated electrically, with larger needles, 0.30 mm×70 mm, being used at BL52 to BL54 in an attempt to reach the deep muscles. The needles were inserted at an angle of about 70° to the surface, and towards the ipsilateral side of the lumbar vertebrae, to avoid trauma to the visceral organs. When a needle was inserted at BL52, she reported *de qi* from 'the muscles causing the pain'. Immediately after removal of the needles she noted that her back was less painful.

When subsequently observed at day 3, she reported that her pain was rapidly improved to 5/10 on movement, and 3/10 on lying. At day 7, she claimed that her pain was resolved.

COMMENT

Muscle strain of the psoas major is suspected as the cause of her back pain, because active flexion of the hip exacerbated pain more than other movements. The needles used in the first session were all 40 mm long, which is too short to reach psoas major.

It is of course essential to know the anatomy of acupuncture points. One study created a reference list of the neuroanatomy and the stratified anatomy for the 361 acupuncture points of 14 channels from several books.² Unfortunately, this list did not mention the acupuncture point responsible for psoas major muscle from the lower back. It lists deep insertion at BL52, BL53, and BL54, BL52 for needling latissimus dorsi, epimysium and iliocostalis lumborum; BL53 and BL54 for gluteus maximus,

epimysium and gluteus medius. No point was mentioned for needling psoas major. After the first session, the author used three cadavers to estimate the anatomical position of psoas major in relation to the lower back. The cadavers were prepared for teaching medical students and were stored at an anatomy laboratory of the author's affiliated institution. The result suggested that psoas major was located at around 4–5 cm lateral to the midline, somewhere between BL52 and BL23, and approximately 5–6 cm deep. However, the accuracy of this estimation was limited by not being able to identify the constitution of the cadavers (either ethnicity or body mass index) because they had been previously dissected. However, it was estimated that needling BL52 at an angle of about 70° would be likely to reach the posterior portion of psoas major muscle. Needling BL53 and BL54 at an angle of about 70° would reach the ilium, not the psoas major.

CAUTION

Inserting an 70 mm needle carries the risk of serious complications: damaging the nerves which exit the intervertebral foramen, including the genitofemoral nerve (anterior rami L1 and L2), lateral cutaneous nerve of the thigh (anterior rami L2 and L3), femoral nerve (anterior rami L2 to L4), and obturator nerve (anterior rami L2 to L4),³ because the proximal parts of these nerves lie on the posterior aspect of the psoas major (figure 1). The other major danger is perforating the intestines or kidneys.

To reduce these risks, needles were inserted at an angle of about 70° towards the ipsilateral side of the lumbar vertebrae. In addition, the patient was asked to report any acupuncture sensation, or painful stimuli. Meanwhile, needles were also inserted slowly and the patient's facial expression was closely monitored so the author could stop inserting the needle when he was informed of any

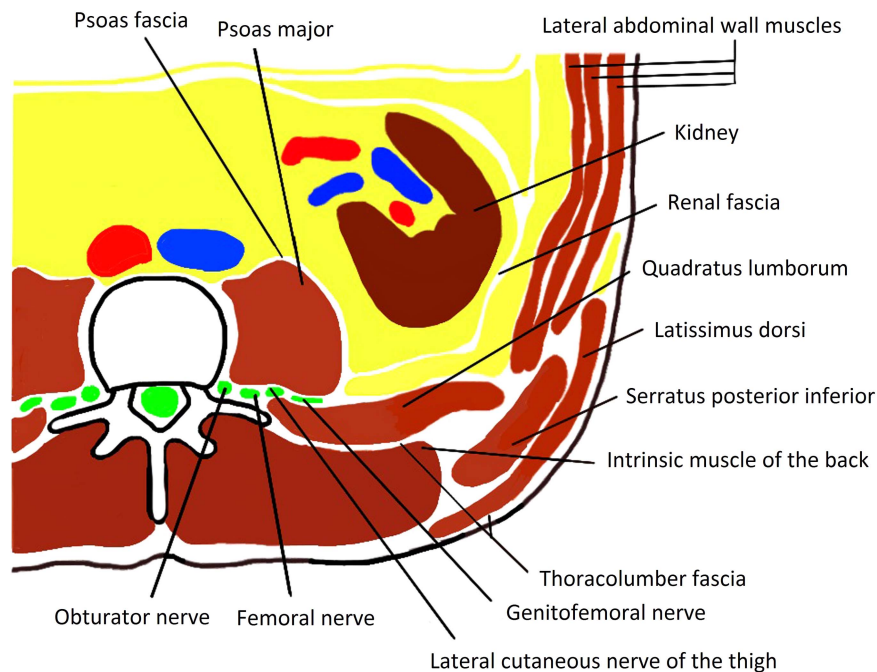


Figure 1 Transverse section at level of L2 superior view.

sensation or pain, or when a painful facial expression of the patient was observed. In planning treatment in this way, body size of the patient should also be taken into account.

The patient reported *de qi* at BL52 only, and her symptoms responded rapidly after that. The response was unlikely to be caused by placebo effect because she did not report any improvement in the first session. It is possible that she responded to stimulation of muscles other than psoas major; ultrasound-guided acupuncture needling was not available to confirm needle location. However it

was definitely deep insertion at BL52 at an angle of 70° that induced the pain relief in this patient.

Kwan Leung Chia

Correspondence to Dr Kwan Leung Chia, School of Medicine, Flinders University, 5 Rider Street, Seacombe Gardens, Adelaide, SA 5047, Australia; chia0104@flinders.edu.au

Competing interests None.

Patient consent Obtained.

Provenance and peer review Not commissioned; internally peer reviewed.

To cite Chia KL. *Acupunct Med* Published Online First: [please include Day Month Year] doi:10.1136/acupmed-2014-010582

Received 11 April 2014

Accepted 2 May 2014

REFERENCES

- 1 Lee JH, Choi TY, Lee MS, *et al.* Acupuncture for acute low back pain: a systematic review. *Clin J Pain* 2013;29:172–85.
- 2 Chapple W. Proposed catalog of the neuroanatomy and the stratified anatomy for the 361 acupuncture points of 14 channels. *J Acupunct Meridian Stud* 2013;6:270–4.
- 3 Darke RL, Vogt W, Mitchell AWM, *et al.* *Gray's anatomy for students*. Philadelphia, PA: Churchill Livingstone Elsevier, 2010:378.



Electroacupuncture treatment of acute low back pain: unlikely to be a placebo response

Kwan Leung Chia

Acupunct Med published online May 15, 2014
doi: 10.1136/acupmed-2014-010582

Updated information and services can be found at:
<http://aim.bmj.com/content/early/2014/05/15/acupmed-2014-010582.full.html>

| | |
|-------------------------------|--|
| | <i>These include:</i> |
| References | This article cites 2 articles http://aim.bmj.com/content/early/2014/05/15/acupmed-2014-010582.full.html#ref-list-1 |
| P<P | Published online May 15, 2014 in advance of the print journal. |
| Email alerting service | Receive free email alerts when new articles cite this article. Sign up in the box at the top right corner of the online article. |

Notes

Advance online articles have been peer reviewed, accepted for publication, edited and typeset, but have not yet appeared in the paper journal. Advance online articles are citable and establish publication priority; they are indexed by PubMed from initial publication. Citations to Advance online articles must include the digital object identifier (DOIs) and date of initial publication.

To request permissions go to:
<http://group.bmj.com/group/rights-licensing/permissions>

To order reprints go to:
<http://journals.bmj.com/cgi/reprintform>

To subscribe to BMJ go to:
<http://group.bmj.com/subscribe/>